

Morphologic Variation of Musculocutaneous Nerve: A Case Report

SHILPA, K, , SUMATHI, S, PRIYA RANGANATH & SAMEER, P. A.

*Department of Anatomy, Bangalore Medical College & Research Institute,
Bangalore 560002, Karnataka*

E-mail: priya_ranganath@rediffmail.com

KEY WORDS: Musculocutaneous nerve. Median nerve. Variation.

ABSTRACT: Musculocutaneous nerve normally pierces the coracobrachialis and runs downwards and laterally between biceps and brachialis, supplying them & continues as lateral cutaneous nerve of forearm. The present report was on a male cadaver from the Department of Anatomy, Bangalore Medical College & Research Institute, Bangalore. On the right side, along with the above pattern, another musculocutaneous nerve arose from the lateral cord of brachial plexus and supplied brachialis through muscular twigs. On the left side, the lateral cord directly gave branches to the coracobrachialis and another branch from median nerve lay between biceps & brachialis, supplied them & became lateral cutaneous nerve of forearm. The knowledge of these kinds of variations is essential for surgeons to avoid any injury to the nerves during surgery or nerve blocks.

INTRODUCTION

The musculocutaneous nerve arises from the lateral cord of the brachial plexus, opposite the lower border of the pectoralis minor, its fibres being derived from the fifth, sixth and seventh cervical nerves. It pierces the coracobrachialis and runs downwards and laterally between the biceps and brachialis supplying these three muscles, to reach the lateral side of the arm; a little beyond the elbow it pierces the deep fascia on the lateral side of the tendon of the biceps and is continued into the forearm as the lateral cutaneous nerve of forearm. The branch to the coracobrachialis leaves the musculocutaneous nerve before that nerve enters the muscle. It receives its fibres from the 7th cervical nerve and in some instances arises directly from the lateral cord of brachial plexus. The branches to the biceps and the brachialis leave the musculocutaneous nerve after it has pierced the coracobrachialis, those supplying the brachialis give a filament to the elbow joint. The nerve also sends a small branch to the humerus, this branch enters the bone with

the nutrient artery¹(Gray's Anatomy). Variations in the formation and branching of brachial plexus are common and have been reported by several investigators.

CASE REPORT

This case was reported during routine dissection on a male cadaver from the Department of Anatomy, Bangalore Medical College & Research Institute, Bangalore. The musculocutaneous nerve on the right side arose from the lateral cord of the brachial plexus, opposite the lower border of the pectoralis minor. It pierced the coracobrachialis and ran downwards and laterally between the biceps and brachialis supplying these three muscles, to reach the lateral side of the arm; a little beyond the elbow it pierced the deep fascia on the lateral side of the tendon of the biceps and continued into the forearm as the lateral cutaneous nerve of forearm. Another musculocutaneous nerve arose below this from the lateral cord of brachial plexus and supplied brachialis through muscular twigs (Fig. 1).

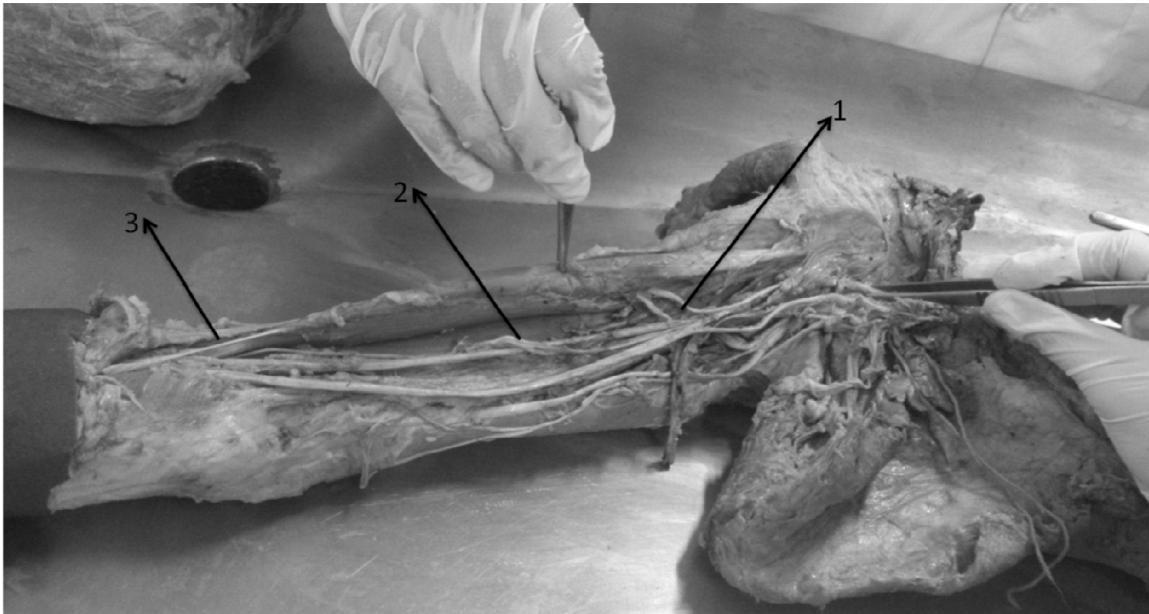


Figure 1: Right side upper limb

1. Musculocutaneous n piercing coracobrachialis & continuing as lateral cutaneous n of forearm (3)
2. Another nerve from lateral cord giving muscular twigs to brachialis

On the left side, the lateral cord directly gave branches to the coracobrachialis and another branch from median nerve lay between biceps and brachialis, supplied them and became lateral cutaneous nerve of forearm (Fig 2).

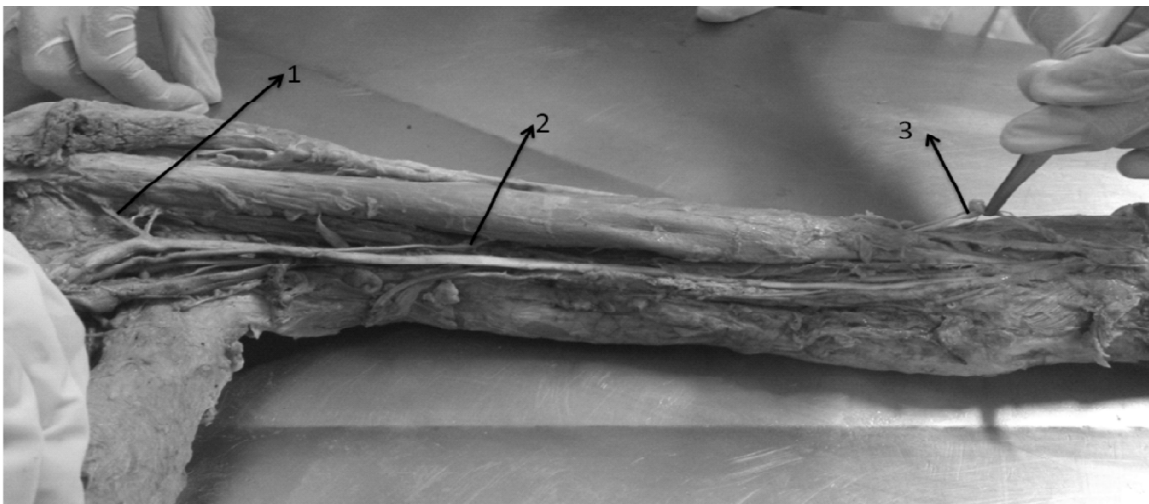


Figure 1: Left side upper limb

1. Muscular branches to coracobrachialis
2. Branch from median n between biceps & brachialis which becomes lateral cutaneous nerve of forearm (3)

DISCUSSION

Many studies have reported variation in the musculocutaneous nerve. There was absence of musculocutaneous nerve in the left arm; the whole lateral cord was joined to the median nerve, which it met in two points. One was a typical junction of both roots of the median nerve at the level of the coracoid process; the other was a junction of the remaining lateral cord and the median nerve² (Song *et al.*, 2003).

A study reported that the musculocutaneous nerve did not pierce the coracobrachialis, which was also seen in the present study and also gave a communicating branch to median nerve^{3,4} (Nakatani *et al.*, '97; Chitra, 2007).

The musculocutaneous nerve arose from the median nerve unilaterally in a male cadaver; in the present study, a similar pattern was seen on the left side⁵ (Tsikaras *et al.*, '83).

Two junctions of the median and musculocutaneous nerves were reported; both roots of the median nerve in a typical place forming one junction with the other formed by lateral cord, with a thick branch off the median nerve located distally. However after branching, musculocutaneous nerve passed through a normal course⁶ (Kaus and Wotowicz, '95).

The motor nerve to the coracobrachialis was seen arising from the lateral cord; and the motor nerve to the biceps brachii and brachialis arose from the median nerve. There was only one junction of the lateral cord and median nerve⁷ (Gumusburun and Adiguzel, 2000).

Complete fusion of median & musculocutaneous nerves was seen in another study; the entire lateral cord was combined with the medial root of the median nerve, forming a common or combined median & musculocutaneous nerve⁸ (Lang and Spinner, '70).

A case of a man who had been stabbed with a small screw driver in the proximal medial aspect of the arm was reported; he had not only complete motor and sensory median nerve deficit but could not contract his biceps brachii or brachialis muscle; this case was a communication of musculocutaneous & median nerves⁹ (Meals and Calkins, '91).

Another study observed the nerve not to pierce the coracobrachialis in 6% of limbs. In 2% of limbs,

the nerve was found to rejoin the median nerve after piercing coracobrachialis¹⁰ (Jamuna and Amudha, 2011).

The musculocutaneous nerve was reported absent and its fibres ran within the median nerve along its course without piercing coracobrachialis¹¹ (Laminor, '90).

Two authors opined that musculocutaneous nerve after piercing coracobrachialis rejoined the median nerve in one case which was also seen by Bhattarai^{12,13} (Joshi *et al.*, 2008; Bhattari and Poudel, 2009).

CONCLUSION

It is important to identify the musculocutaneous nerve as it is vulnerable to injury from retractors which are placed under the coracoid process, during coracoid process grafting, shoulder dislocations, anterior approach for the fracture of humerus and frequent arthroscopies. Hence knowledge of these variations is important for neurologists, orthopedicians and traumatologists. They also have clinical importance in post traumatic evaluations and exploratory innervations of the arm for peripheral nerve repair.

REFERENCES

- Bhattarai, C. and P. P. Poudel 2009. Unusual variations in the musculocutaneous nerve. *Katmandu University Medical Journal*, 7, 4(28): 408-410.
- Chitra, R. 2007. Multiple bilateral neuroanatomical variations of nerves of the arm. *Neuroanatomy*, 6: 43-45.
- Gray's Anatomy*, 36th ed., p. 1097. Williams & Warwick, Churchill Livingstone: Edinburgh.
- Gumusburun E, and E. Adiguzel E. 2000. A variation of the brachial plexus characterized by the absence of the musculocutaneous nerve: A case report. *Surg Radiol Anat.*, 22: 63-65.
- Jamuna, M. and G. Amudha 2011. A cadaveric study on the anatomic variation of the musculocutaneous nerve in the infraclavicular part of brachial plexus. *Journal of clinical and diagnostic research*. 5(6): 1144-1147.
- Joshi, S. D., S. S. Joshi and S.A. Athavale 2008. Hitch-hiking fibres of the lateral cord of brachial plexus in search of their destination. *J. Anat. Spoc. India*, 57: 26-29.
- Kaus, M., Z. Wotowicz 1995. Communication branch between the musculocutaneous and median nerves in human. *Folia Morphol.*, 54: 273-277.
- Lang, J. and M. Spinner 1970. An important variation of the brachial plexus – complete fusion of the median &

- musculocutaneous nerve. *Bull. Hosp. Jt. Dis. Rtho. Inst.*, 1970; 31: 7-13.
- Leminor, J. M. 1990. A rare variation of the median nerve & the musculocutaneous nerves in man. *Archives Anatomy Histology Embryology*, 73: 33-42.
- Meals, R. A. and E. R. Calkins 1991. Anomalous innervation of the upper extremity. In: R. Gelberman (ed.), *Operative Nerve Repair & Reconstruction*, p. 199-200. Lippincott: Philadelphia.
- Nakatani, T., S. Muzukami and S. Tanaka 1997. Three cases of musculocutaneous nerve of perforating the coracobrachialis muscle. *Kaibogaku Zasshi*, 72: 191-194.
- Song, W. C., H. S. Jung, H. J. Kim, C. Shin, B. Y. Lee and K. S. Kho 2003. A variation of the musculocutaneous nerve – absent. *Yonsei Medical Journal*, 44(6): 1110-1113.
- Tsikaras, P. D., A. S. AGiabasis and P.M. Hytioglou 1983. A variation in the formation of brachial plexus characterised by the absence of C8 & T1 fibres in the trunk of the median nerve. *Bull. Assoc. Anat. (Nancy)*, 67: 501-505.